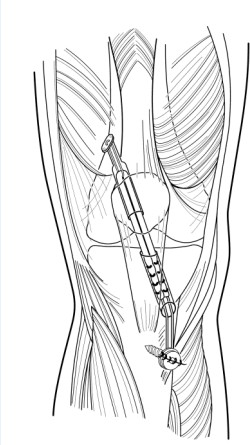
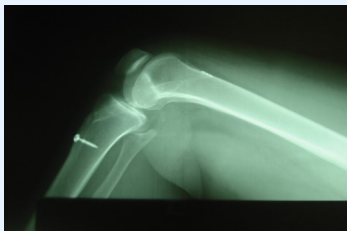

**Surgical notes:** A tiny button is implanted on the thighbone and cannot be felt. A titanium screw is implanted in the tibia--the leg bone. This screw may be findable by rubbing over it, but in our study of 150 consecutive cases no patient had wanted it removed or had complaints regarding it. Most of the surgery is done arthroscopically, using a small operating telescope inserted through three ¼-inch punctures into the knee. No knee incision is otherwise used.



**Associated injuries:** In about half of the cases, a meniscal cartilage injury will be found. This is easily trimmed or repaired as needed during surgery. Sometimes defects in the coating of the bone, called the articular cartilage, are found. These defects are smoothed, or a microfracture may be performed to regenerate new cartilage. A subsequent articular cartilage implantation may also be necessary in rare instances.



**Post-operative rehabilitation:** After surgery, weight bearing and leg motion are rapidly initiated. Most people can return to school or sedentary jobs within a few days of the surgery. Physical therapy will be prescribed to restore motion and strength. In most cases, full sports activities are resumed in six months.

**Risks:** Infections can occur in about one per cent of cases. In our recent studies, no infections were found. A rare occurrence could be stiffness, which might require an additional procedure be performed. Other rare complications such as nerve injury or reflex sympathetic dystrophy also can occur. Graft failure is noted in the orthopedic literature to occur in about five percent of all ACLR cases. In a two- to nine-year follow-up study of more than 200 ACLRs done at our clinic, however, we did not have a single instance of graft failure.

**Pain relief:** Hydrocodone and acetaminophen are used for pain relief in tablet form. Also a special pad and cooler are used to continuously pump ice water around the knee both in the hospital and at home for the first week.



*Anterior Cruciate Ligament Reconstruction*

*Illinois  
Sportsmedicine and  
Orthopaedic Center*

## *Anterior Cruciate Ligament Reconstruction (ACLR)*

1714 Milwaukee Ave.  
Glenview, IL 60025

Phone: 847-699-6810  
Fax: 847-699-6545  
Website: [www.ISMOC.net](http://www.ISMOC.net)

## Anterior Cruciate Ligament Reconstruction (ACLR)

**Definition of anterior cruciate ligament:** The structure that holds the knee together during pivoting and jumping. When it is torn, the knee may be unstable during these activities.

**Consequences of a torn ACL:** When the knee “goes out,” cartilage is often torn. This eventually can result in arthritis of the knee. In severe cases, total knee replacement may be necessary to restore function and relieve pain.

**Diagnosis:** A recent study from our clinic confirms that the KT 1000 arthrometer is nearly 100% diagnostic of ACL tears. MRI is an option as well. However, MRIs can give a false negative result. In our study, MRIs erroneously showed in about one-fifth of our ACL patients, that the ACL was intact when it was in fact torn. For this reason we only perform MRIs in special circumstances, or if the patient requests.

**Anterior cruciate ligament reconstruction:** Repair of a torn ACL is ineffective. But reconstructing the ACL with a tendon graft reliably restores knee stability. At Illinois Sportsmedicine we use hamstring grafts exclusively for this procedure.

**Types of grafts—Hamstring:** A helper hamstring tendon and a helper adductor tendon are removed from the thigh and used to make a new ACL. With proper rehabilitation, there should be no strength deficit or other problem as a result of removing this graft.

—**Patellar tendon:** Patellar tendon grafts with a piece of the patella and a piece of the tibia are also used successfully by many orthopedists to reconstruct the ACL.

**Why we use the hamstring graft:** The hamstring graft is stronger than the patellar tendon graft. Its material properties (modulus of elasticity) also more closely resemble the native ACL than the patellar tendon graft. On rare occasions, the patellar tendon graft can be associated with complications. These include fracture of the patella (as happened to all-pro NFL receiver Jerry Rice) or rupture of the remaining patellar tendon. No complications have been found to occur from taking the hamstring graft. Additionally, patellar pain and stiffness are generally found to be higher using the patellar tendon graft than the hamstring graft. Both the hamstring graft and patellar grafts are excellent procedures when properly performed. Cadaver, allo, grafts are used by some. They have worse results regarding stability and a small risk of disease transmission. We do not use them.

**Type of procedure:** The surgery is done on an outpatient basis at a hospital or surgicenter. The patient goes home later on the same day the procedure is performed.

**Anesthesia:** General anesthesia (putting the patient to sleep) is the usual anesthetic method. It is also possible for the patient to have an injection into the lower back for spinal or epidural anesthesia.

**Surgical mini-incisions:** Dr. Prodromos developed a mini-incision technique he uses for this procedure. He uses a small incision hidden in the back of the knee and a small incision over the upper shin. Both are usually only about one inch in size. One year after surgery both are usually inconspicuous and often nearly invisible.

